

Hamsu Kadriyan 3 International Journal

by Hamsu Kadriyan 3

Submission date: 07-Aug-2022 12:21PM (UTC+0700)

Submission ID: 1879634615

File name: Hamsu Kadriyan 3 International Journal.pdf (1.85M)

Word count: 4610

Character count: 24952

RESEARCH ARTICLE

Purple Sweet Potato Reduces Malondialdehyde and TNF- α , Increases p53, and Protects Histopathological Appearance in Formaldehyde-induced Nasopharyngeal Carcinoma Rats

Ni Ketut Susilawati^{1,*}, I Wayan Putu Sutirta Yasa², Wayan Suardana³, Sri Maliawan²,
I Made Jawi², Achmad Chusnu Romdhoni⁴, Hamsu Kadriyan⁵,
I Wayan Gede Artawan Eka Putra⁶, I Gusti Kamasan Nyoman Arijana⁷

¹Department of Otorhinolaryngology - Head and Neck Surgery, Praya Regional General Hospital, Jl. H. Lalu Hasyim, Praya 83511, Indonesia

²Faculty of Medicine, Universitas Udayana, Jl. P.B. Sudirman, Denpasar 80232, Indonesia

³Department of Otorhinolaryngology - Head and Neck Surgery, Sanglah General Hospital, Jl. Diponegoro, Denpasar 80113, Indonesia

⁴Faculty of Medicine, Universitas Airlangga, Jl. Mayjen Prof. Dr. Moestopo No.47, Surabaya 60132, Indonesia

⁵Faculty of Medicine, Universitas Mataram, Jl. Majapahit No.62, Mataram 83125, Indonesia

⁶Public Health Study Program, Faculty of Medicine, Universitas Udayana, Jl. P.B. Sudirman, Denpasar 80232, Indonesia

⁷Department of Histology, Faculty of Medicine, Universitas Udayana, Jl. P.B. Sudirman, Denpasar 80232, Indonesia

*Corresponding author. E-mail: susilawaketut88@gmail.com

7

Received date: Apr 18, 2022; Revised date: Jun 6, 2022; Accepted date: Jun 7, 2022

Abstract

BACKGROUND: Purple sweet potato tuber ethanol extract (PSPTEE) has been known to have benefits in various disease, including to prevent nasopharyngeal carcinoma (NPC). However, there has been no research on PSPTEE in preventing the proliferation of nasopharyngeal mucosal epithelial cells induced by formaldehyde through the oxidative stress mechanisms and inflammatory process. Studies have proven the effect of PSP on various cancer cells, but the carcinogenesis process of the nasopharyngeal mucosal epithelium is still limited. Hence, this study aimed to demonstrate the mechanism for preventing histopathology changes with PSPTEE due to formaldehyde exposure.

METHODS: Thirty-two formaldehyde-induced Wistar rats were treated with or without 1g/kgBW/day PSPTEE for 16 weeks. Malondialdehyde (MDA) level were examined with spectrophotometry method, while tumor necrosis factor (TNF)- α and p53 with enzyme linked immunosorbent assay (ELISA) method. The histopathology appearance of the nasopharyngeal epithelium was observed with hematoxylin-eosin (HE) staining.

RESULTS: MDA and TNF- α levels in control and treatment group were 22.89 \pm 2.84 μ M; 9.83 \pm 0.89 μ M and 84.18 \pm 11.58 ng/L; 73.92 \pm 10.59 ng/L, respectively, and they showed significant difference. Meanwhile, the level of p53 showed no significant difference. Histopathology appearance showed a significant difference. Path analysis for MDA, TNF- α and p53 levels contributed 28.7% to histopathology appearance. MDA have an effect on significant direct effect on TNF- α . TNF- α has a significant direct effect to histopathological appearance. Indirect influence MDA on histopathological appearance were smaller than the direct effect. TNF- α has the greatest influence on histopathological appearance.

CONCLUSION: Formaldehyde induces the histopathology appearance in nasopharyngeal epithelium. This study also demonstrates the mechanism to prevent the nasopharynx epithelial histopathology appearance by administration of PSPTEE.

KEYWORDS: PSP, MDA, TNF- α , p53, nasopharynx epithelial

Indones Biomed J. 2022; 14(2): 211-7

Introduction

In Indonesia, 348,809 new cases and 207,210 deaths are caused by nasopharyngeal carcinoma (NPC) every year.(1) The causes of NPC are multifactorial, including genetic, viral and environmental factors.(2,3) Risk factors and carcinogenic materials that have the potential to cause NPC have been reported by many experts, one of which is formaldehyde.

Formaldehyde as a free radical can cause oxidative stress. Oxidative stress could induce DNA and biomolecular damage, genetic instability and subsequent cell death can occur, namely apoptosis, senescence and autophagy. It also causes inflammation, cellular transformation, differentiation, proliferation, tumor promotion, angiogenesis, immune response, tissue invasion and metastasis.(4) Oxidative stress is determined by malondialdehyde (MDA) level. (5) According to inflammation effect of formaldehyde, it may relate to tumor necrosis factor (TNF)- α as one of the inflammation mediators. TNF- α is acting by activation of nuclear factor- κ B (NF- κ B). Continuous activation of NF- κ B can cause inflammation and mucosal damage. At a later stage it can promote the proliferation of cancer cells, prevent apoptosis, drug resistance, increase angiogenesis and tumor metastasis.(6)

In stressed cells, p53 will be activated. When DNA damage occurs, p53 plays an important role in determining whether DNA will be repaired or damaged cells will undergo apoptosis. If DNA can be repaired, p53 will activate other proteins to repair the damage. If the DNA can not be repaired, this protein will induce cell apoptosis, by stopping cell mutation or replication of damaged DNA.(7)

To prevent oxidative stress, antioxidants are needed. One of the interesting antioxidants that need to be explored is the purple sweet potato (PSP) tuber (*Ipomea batatas* L) due to its high anthocyanin content. Based on the previous research, PSP tubers planted in Bali, Indonesia, have anthocyanin levels ranging from 110 mg/100 grams to 210 mg/100 grams.(8) Until now, many studies on the role of PSP tuber ethanol extract (PSPTEE) in preventing inflammation and apoptosis have been carried out. Several studies have proven the effect of PSP, it was found that sweet potato enriched with anthocyanin P40 can prevent colorectal cancer by suppressing the cell cycle through anti proliferative mechanisms and apoptosis.(9) PSPTEE also could inhibit the proliferation of T47D breast cancer cells *in vitro*.(10) PSPTEE showed anti-inflammatory activity by suppressing the production of nitric oxide (NO) and proinflammatory

cytokines such as NF- κ B, TNF- α and interleukin (IL)-6 in lipopolysaccharide (LPS) induced macrophage cells in breast cancer cells, gastric cancer, colon adenocarcinoma. (11,12) Several studies have proven the effect of PSP on various cancer cells, but the carcinogenesis process of the nasopharyngeal mucosal epithelium is still limited. Therefore, it is important to conduct research to determine the mechanism of formaldehyde causing histopathological changes in the epithelium of the nasopharyngeal mucosa and the mechanism of prevention by administration PSPTEE in view of oxidative stress by examination of MDA, the mechanism of inflammation by examination of TNF- α and the mechanism of apoptosis by examination of p53 in Wistar rats induced by formaldehyde.

Methods

Animal Treatment

Thirty-two formaldehyde-induced Wistar rats were included in this experimental study and divided into two groups, with 16 rats in each. Rats in the control group were induced with 20 ppm 10% formaldehyde and given distilled water for 16 weeks. Meanwhile, the rats in the treatment group were induced by 10% formaldehyde and administered with 1g/kgBW/day PSPTEE for 16 weeks. Formaldehyde induction was carried out by inhalation 20 ppm 10% formalin solution in a semi-enclosed space with a volume of 0.06 m³, given 6 hours per day for 16 weeks. Based on previous research, 16 weeks formalin induction has been able to induced dysplasia.(13) At the end of the study, all rats were sacrificed, then blood plasma was taken for MDA examination, while the serum was taken for TNF- α and p53 examination, and nasopharyngeal mucosal epithelial tissue was excised for a histopathology examination. Ethical clearance was obtained from Animal Ethics Committee Faculty of Veterinary Medicine (No. B/108/UN14.2.9/PT.01.04/2021).

MDA, TNF- α and p53 Examinations

MDA levels were observed by dissolving blood plasma with 100 mL of 20% TCA, 250 mL of 1N HCl and 100 mL of 1% Na-TBA and measured with a UV mini-1240 spectrophotometer (Shimadzu, Kyoto, Japan). Double beam cuvette was to stored samples and blanks. The light detector or reader processed light data into numbers.

Examination of Rat TNF- α was conducted using the enzyme linked immunosorbent assay (ELISA) method, with the Rat TNF- α BT-LAB ELISA kit (Cat No. E0764Ra, Bioassay Technology Laboratory, Changsheng, China).

Preparation of standard solutions was done by preparing 5 microtubes and adding 120 μL of standard diluent, then vortexed. Fifty μL of standard solution, 50 μL of standard diluents, 40 μL of sample solution, 10 μL of anti-TNF- α antibody, 50 μL of Streptavidin-HRP were added and mixed homogeneously before incubated at 37°C for 60 minutes. After washed, 50 μL of substrate A and 50 μL of substrate B were added incubated for 10 minutes at 37°C and followed by adding 50 μL of stop solution.

Examination of Rat Tumor Protein53/p53 (TP53/p53) using an Rat p53/TP53 BT-LAB ELISA kit (Cat No. E00071Ra, Bioassay Technology Laboratory). The principle was similar to TNF- α examination, the difference was only in the use of an anti-p53 antibody.

Histopathological Examination

The histopathological preparations were colored with hematoxylin-eosin (HE) staining, and photographed using an Olympus CX41 microscope (Olympus, Tokyo, Japan) and Optilab Pro camera using Optilab Pro software (Miconos Company, Yogyakarta, Indonesia). The preparations were interpreted based on histopathological scores. The score criteria were: score 0 = normal, score 1 = hyperplasia, score 2 = metaplasia, score 3 = mild dysplasia, score 4 = moderate dysplasia, score 5 = severe dysplasia, score 6 = *ca in situ*, score 7 = squamous cell carcinoma (SCC).

Statistical Analysis

After the examination, the data were obtained and statistically analyzed using the Statistical Package for the Social Sciences (SPSS) version 22 for Windows program (IBM Corporation, Armonk, NY, USA). Shapiro-Wilk test was used to test the data distribution. The statistical test used to analyze the difference of MDA and TNF- α levels was the independent t-test. The statistical test used to analyze the difference of p53 levels was the Mann-

Whitney U test. Meanwhile, the statistical test used for the degree of histopathology appearance in the epithelium of the nasopharyngeal mucosa was Fisher's exact test. Path analysis was done using the multiple regression analysis test to determine the direct or indirect effect of plasma MDA levels on TNF- α and p53 levels and their impact on histopathology changes in the nasopharyngeal mucosal epithelium.

Results

Based on this study, formaldehyde induced changes in the epithelium of the nasopharyngeal mucosa (Figure 1). In the control group, moderate dysplasia was found in most of the sample (56.3%). While in the treatment group, mild dysplasia was found in most of the sample (56.3%). Severe dysplasia was found in both control group 18.8% and treatment group (6.3%) (Figure 2). According to Fisher's Exact test, the difference between both groups was significant ($p < 0.05$).

According to the spectrophotometric examination, the lowest and the highest MDA level in control group and treatment group were 17.04 μM and 26.59 μM ; 8.65 μM and 11.99 μM , respectively. The mean MDA levels of the treatment group were lower than the control group consecutively at $9.83 \pm 0.89 \mu\text{M}$ and $22.89 \pm 2.84 \mu\text{M}$ (Table 1). Based on the T-test analysis, the difference was significant ($p < 0.05$).

The lowest and the highest level of TNF- α in control group was 65.212 ng/L and 100.073 ng/mL, whereas in the treatment group was 49.442 ng/L and 89.455 ng/L. The average TNF- α level in the treatment group was lower than in the control group ($84.14 \pm 11.58 \text{ ng/L}$ vs. $73.92 \pm 10.59 \text{ ng/L}$). The t-test found a significance difference between both groups with a $p < 0.05$ (Table 1).

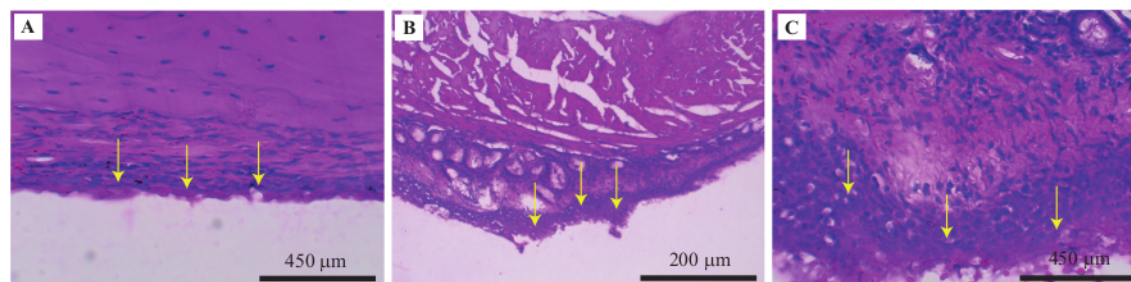


Figure 1. Histopathological appearance of nasopharyngeal mucosal epithelium. A: Morphology of normal cells nasopharyngeal epithelial. B and C: Morphology of severe dysplasia. Yellow arrow: nasopharyngeal mucosal epithelium.

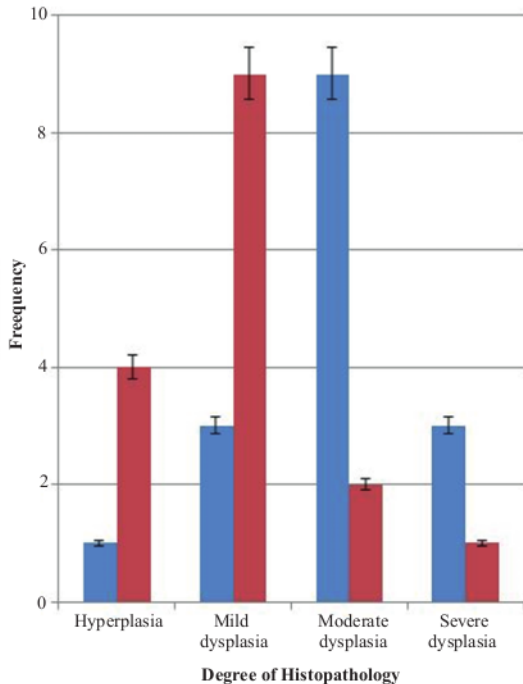


Figure 2. Degree of histopathology appearance in the nasopharyngeal mucosal epithelium of Wistar rats.

The level of p53 in the treatment group was higher than in the control group. However, the results of the Mann-Whitney U-test found no significance difference between both groups with $p > 0.05$ (Table 1).

The result of path analysis showed the direct or indirect effect of MDA, TNF- α and p53 levels on histopathology appearance in the nasopharyngeal mucosa (Figure 3). MDA had a significant direct effect on TNF- α . The contribution of MDA levels to TNF- α was 17%, while the remaining 83% was the contribution of other variables which was not explored in this study. The direct effect of TNF- α levels was significant on histopathology appearance $p < 0.05$. The levels of MDA, TNF- α and p53 contributed 28.7% to the histopathology changes. The indirect effect of MDA levels on histopathology appearance was smaller than the direct effect.

Table 1. Results of data analysis on MDA, TNF- α and p53 levels.

Parameter	Control Group (n=16)	Treatment Group (n=16)	p-value
MDA level (μ M), mean \pm SD	22.89 \pm 2.84	9.83 \pm 0.89	0.000*
TNF- α level (ng/L), mean \pm SD	84.18 \pm 11.58	73.92 \pm 10.59	0.014*
p53 level (pg/mL), median (min-max)	51.39 (35.44-109.30)	66.87 (43.73-86.37)	0.851

*statistically significant, $p < 0.05$. Tested with T-test for MDA and TNF- α , Mann-Whitney test for p53.

Discussion

In several studies on formaldehyde, giving 10% formalin steam and a standard diet plus 54 mg/kg BW formalin for 9 weeks can result in histopathology changes in the nasopharyngeal mucosal epithelium into severe dysplasia. (13) Research on the harmful effects of formaldehyde and the effect of administering black cumin (*Nigella sativa*) on the trachea showed that the most apoptotic activity occurred at a dose of 10 ppm, 8 hours per day for 13 weeks, distortion of the tracheal epithelium and loss of cilia in the surface epithelium in all groups. (14)

Formaldehyde is a free radical that caused oxidative stress. The present of an oxidative stress indicated by the expression of MDA. (5) In this study, there was a significant difference in MDA levels in rats induced by 10% formaldehyde between ethanol extract of PSP tubers administration compared to the control group. This condition may occur because the level of MDA is dependent on the amount of oxidative stress. On the other hand, oxidative stress can be neutralized by antioxidants. (15) Likewise, the study of PSPTEE can reduce MDA levels in the liver of rats under chronic alcohol administration. (8) Our results are in line with research on extracts of PSP water that reduced the MDA and IL-1 levels in hypercholesterolemic rabbits. (16) In advance, in our study could be associated with a decrease in histopathological damage in the nasopharyngeal mucosa. Based on the theory that lower MDA levels caused MDA cross-linking with DNA to be prevented. This is consistent with the results in this study, where the levels of MDA in the treatment group were lower than the control group. The association between variables can be seen in Figure 4.

It's well known that TNF- α is the main mediator of inflammation. (17) This is in line with the study on TNF- α which are proinflammatory and immune regulatory cytokines, may contribute to the pathogenesis of recurrent inflammatory in an otitis media suppurative chronic. (18) In our study there was a significant difference between the average levels of TNF- α in the treatment group and the control group. So, it is postulated that the administration

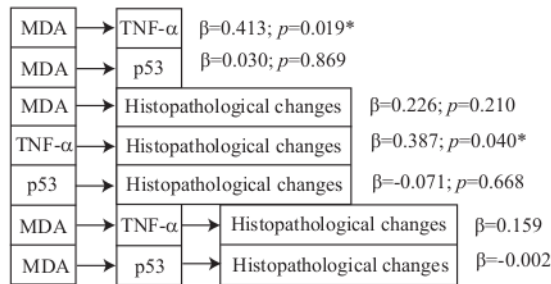


Figure 3. Path analysis of MDA, TNF- α and p53 levels on histopathology appearance in the nasopharyngeal mucosa. β : the influence power; *statistically significant ($p < 0.05$), tested with multiple regression analysis test.

of PSPTEE can prevent the increase of TNF- α . This is in line with the study on caffeic acid could be a potent osteoclastogenesis inhibitor through inhibition of NF- κ B activity.(19) This is in line with the study on the rats exposed to cigarette smoke and treated with 0.14 g of PSPL (PSP leaves) flour. Reported that the levels of TNF- α , IL-6 and NF- κ B were associated with the administration of this substance.(20) With the reduced of MDA, inflammation can be prevented through inhibition of TNF- α binding with the TNF-R1 receptor. Hence, there is no recruitment of the TNF-R1 adapter protein associated death domain protein (TRADD) and TNF receptor associated factor (TRAF2). As a result, it will inhibit the I κ B kinase (IKK) and MEKK3/6 through receptor interacting protein (RIP). Then, it will inactivate NF- κ B and MAPK.(6)

In the present results, it was found that the median (IQR) of p53 in the group of rats induced by formaldehyde and given the PSPTEE were higher than the control group, although there was no significant difference between both groups. It may alter by the abnormal data distribution or due to other biomarkers that were not included in this study. When compared to other studies, the PSPTEE increased the p53 levels, such as the study of curcumin (*Curcuma longa*) which increased the expression of p53 and p21 in DNA binding.(21) In our study, p53 levels in the treatment group were higher than in controls. Wild type p53 plays an important role in the process of cell cycle arrest, DNA repair, apoptosis and senescence. Mutant type may cause the delay of apoptosis and induction of cell proliferation. It is necessary to explore the type of p53 because it was declared that mutant type could be found in NPC through the nano vesicle namely exosome. Furthermore, it was found that the insertion of a G base on exon 5 at codon 180 allows a change in the base sequence from GAG to GGA. This change will cause a change in the character of p53.

(22) The prevalence of p53 mutations in head and neck malignancies has been reported to range from 39-62%.(23) The administration of the PSPTEE can affect p53 levels through the anti-carcinogenic activity of anthocyanins in the early stages of tumorigenesis. Anthocyanin plays a role as an antioxidants, anti-inflammatory and anti-mutagenesis. If the antioxidant binds to free radicals, it will reduce the damage to the normal cell genome due to oxidative stress and malignant disease as well as the transformation by a gene mutation. As a result, antioxidants could play a role in the prevention of the tumor's growth. Furthermore, they play a role in antioxidant protection. In summary, the promotion of antioxidant response element (ARE)-regulated phase II enzyme expression by anthocyanins plays a role in the protection of normal cells from oxidative stress exposure.(24)

Cyanidin and peonidin, the active compound of anthocyanins contained in PSP tubers have an antimutagenic property. During the transformation of normal cells into cancer cells, hypermutation occurs on somatic cells that can induced genome instability and promote cancer growth.(24) On the other hand, the anti-carcinogenic activity of anthocyanins at the stage of cancer formation was done through differentiation induction, inhibition of cellular transformation and inhibition of cell proliferation. The main manifestations of anthocyanin inhibition on cancer growth and proliferation include the inhibition of signaling pathways to block signal transduction and regulate the expression of anti-oncogenes and other signaling pathways. The anti-carcinogenic activity of anthocyanins in an advanced stage of cancers development includes the induction of mitochondrial-mediated tumor cell apoptosis by dependent and independent caspase pathway.(24) This is in line with the study on *Momordica charantia* L fruit fractions inhibit the MDA level average in liver tissue and regenerate hepatic damage of STZ induced rats.(25) The above study is similar to our finding on PSPTEE. In normal cells without oxidative stress, p53 expression was very low. On the other hand, under stress conditions, p53 will be activated, then promote the termination of the cell cycle through p21 transcription and DNA repair through GADD45 transcription. Therefore, cell proliferation will run well. If it cannot be repaired and under severe stress conditions, p53 together with pro apoptotic genes will facilitates apoptosis.(7) Among the antioxidants that have been found to decrease anti-inflammatory factors, PSPTEE has high levels of anthocyanins, anthocyanins are part of the flavonoid family. Two important components of anthocyanins are cyanidin and peonidin, have been proven to be antioxidant. Anthocyanins can be used as a mixture of

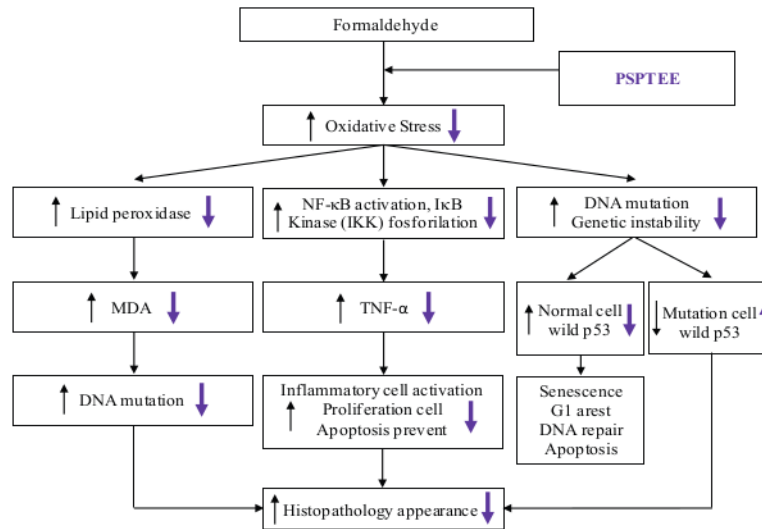


Figure 4. The relationship between variables after given formaldehyde and PSPTEE. Formaldehyde causes an increase in oxidative stress and then increases lipid peroxidase, increasing MDA. MDA binds to DNA, causing DNA mutations and affecting more severe histopathological features. Oxidative stress activates NF- κ B, increases TNF- α then activates inflammation, proliferation, prevents apoptosis so that the histopathological appearance to be more severe. Oxidative stress increases DNA mutations, in normal cells increases activation of wild p53 and in mutated cells increases the inactivation of wild p53 so that it will affect the histopathological appearance to be more severe. With the administration of PSPTEE in the process, the opposite alteration will happen.

staple foods, can be processed in various forms of attractive products, easy to obtain, easy to cultivate, affordable prices and has been proven by many studies as antioxidants and anti-inflammatory.(8,24)

In this study, the exposure time might not optimal because the squamous cell carcinoma was not formed yet. Further research is needed to explore more detail regarding the safety properties of PSP extract, the effective dose and the other biomarker that may altered the result of this finding. The comparison of formaldehyde exposure with control group is also necessary to be studied in order to knows exact effect of PSPTEE on histopathology changes in nasopharyngeal mucosa.

Conclusion

This study demonstrates that formaldehyde acts as a mutagenic substance by promoting the histopathologic appearance in the epithelium nasopharyngeal mucosal. The administration of PSPTEE reduces the histopathology appearance of of nasopharyngeal mucosal epithelium. The PSPTEE has antioxidant and anti-cancer effects through its reduction of MDA and TNF- α expression and p53 expression. According to this result, PSPTEE has potency as an alternative therapy with its natural ingredients in the prevention of tumorigenesis processes.

Authors Contribution

NKS, WPS, WS, SM, IMJ, ACR were involved in conceiving the study, developing the manuscripts, and took parts in giving critical review. NKS, GKA conducted laboratory tests. HK, ACR took parts in giving critical review. WGA did the statistical analysis. All authors agree to the final version of the manuscript.

References

1. UICC Global Cancer Control [Internet]. Global Cancer Data: GLOBOCAN 2018 [cited 2019 Sep 23]. Available from: <https://www.uicc.org/news/global-cancer-data-globocan-2018>.
2. Adham M, Kurniawan AN, Muhtadi AI, Roezin A, Hermani B, Gondhowiardjo S, *et al.* Nasopharyngeal carcinoma in Indonesia: epidemiology, incidence, signs, and symptoms at presentation. *Chin J Cancer.* 2012; 62(4): 185-96.
3. Al Azhar MA, Nadliroh S, Prameswari K, Handoko H, Tobing DL, Herawati C. Profile of PD-1 and PD-L1 mRNA expression in peripheral blood of nasopharyngeal carcinoma. *Mol Cell Biomed Sci.* 2020; 4 (3): 121-7.
4. Ríos-Arrabal S, Artacho-Cordón F, León J, Román-Marinetto E, Del Mar Salinas-Asensio M, Calvente I, *et al.* Involvement of free radicals in breast cancer. *Springerplus.* 2013; 2: 404. doi: 10.1186/2193-1801-2-404.
5. Niedernhofer LJ, Daniels J, Rouzer CA. Malondialdehyde a product of lipid peroxidation, is mutagenic in human cells. *J Biol Chem.*

- 2003; 278(33): 31426-33.
6. Wu Y, Zhou BP. TNF- α /NF- κ B/Snai1 pathway in cancer cell migration and invasion. *Br J Cancer*. 2010; 102(4): 639-44.
 7. Liu D, Ou L, Clemenson Jr GD, Chao C, Lutske ME, Zambetti GP, *et al*. Puma is required for p53-induced depletion of adult stem cells. *Nat Cell Biol*. 2010; 12(10): 993-8.
 8. Yasa IWPS, Jawi IM, Ngurah IB, Subawa AAN. Balinese purple sweet potato (*Ipomoea batatas* L) on SGOT, SGPT, MDA level and chronic alcohol. *Indones J Clinical Pathol Med Laboratory*. 2011; 3(17): 151-4.
 9. Lim S, Xu J, Kim J, Chen TY, Su X, Standard J, *et al*. Role of anthocyanin-enriched purple-fleshed sweet potato p40 in colorectal cancer prevention. *Mol Nutr Food Res*. 2013; 57(11): 1908-17.
 10. Sumardika IW, Indrayani AW, Jawi IM, Suprpta DN, Adnyana L. Efek sitotoksik dan antiproliferasi ekstrak etanol umbi ubi jalar ungu (*Ipomoea batatas* L) terhadap sel line kanker payudara T47D. *Jurnal Penyakit Dalam*. 2010; 11(1): 25-32.
 11. Sugata M, Lin CY, Shih YC. Anti-inflammatory and anticancer activities of Taiwanese purple-fleshed sweet potatoes (*Ipomoea batatas* L.) extracts. *BioMed Res Int*. 2015; 2015: 768093. doi: 10.1155/2015/768093.
 12. Sandra F, Sidharta MA. Caffeic acid induced apoptosis in MG63 osteosarcoma cells through activation of caspases. *Mol Cell Biomed Sci*. 2017; 1(1): 28-33.
 13. Sapmaz E, Zapmas HI, Vardi N, Tas U, Sarsimas M, Toplu Y, *et al*. Harmful effect of formaldehyde and possible protective effect of *Nigella sativa* on the trachea of rats. *Niger J Clin Pract*. 2017; 20(5): 523-9.
 14. Sulisty H. Inhibisi Aktivitas Proliferasi Sel dan Perubahan Histopatologi Epitelial Mukosa Nasofaring Mencit C3H Dengan Pemberian Ekstrak Benalu Teh [Thesis]. Semarang: Universitas Diponegoro; 2008.
 15. Olive S. Profile of MDA (malondialdehyde) levels as a marker of cellular damage due to free radicals in rats given oxygenated water. *J Bio-Sci Med Anal*. 2018; 5(1): 79-84.
 16. Jawi IM, Indrayani W, Yasa IWPS. Aqueous extract of Balinese purple sweet potato (*Ipomoea batatas* L) prevents oxidative stress and decreases blood interleukin-1 in hypercholesterolemic rabbits. *Bali Med J*. 2015; 4(1): 37-40.
 17. Aggarwal BB, Gupta SC, Ji, Kim H. Historical perspectives on tumor necrosis factor and its superfamily: 25 years later, a golden journey. *Blood*. 2012; 119(3): 651-65.
 18. Pratiwi D, Rizqiana M, Wicaksono A, Permatasari D, Restuti RD, Susilawati TN, *et al*. TNF- α dan TGF- β in contributes in recurrent otorrhea of active mucosal chronic otitis media. *Indones Biomed J*. 2022; 14(1): 59-65.
 19. Sandra F, Kukita T, Tang QY, Iijima T. Caffeic acid inhibits NF- κ B activation of osteoclastogenesis signaling pathway. *Indones Biomed J*. 2011; 3(3): 216-22.
 20. Kusumastuty I, Adi P, Harti LB, Nugroho FA. Pengaruh pemberian daun ubi jalar ungu (*Ipomoea batatas* Lam) terhadap kadar TNF- α , IL-6 dan NF- κ B pada tikus yang dipapar asap rokok. *Jurnal Kedokteran Brawijaya*. 2015; 28(3): 228-32.
 21. Jee SH, Shen SC, Tseng CR, Chiu HC, Kuo ML. Curcumin Induces a p53-dependent apoptosis in human basal cell carcinoma cells. 1998; 111(4): 656-61.
 22. Kadriyan H, Prasedya ES, Pieter NAL, Gaffar M, Akil A, Bukhari A, *et al*. NPC-exosome carry wild and mutant-type p53 among nasopharyngeal cancer patients. *Indones Biomed J*. 2021; 13(4): 403-8.
 23. Smith EM, Wang D, Rubenstein LM, Morris WA, Turek LP, Haugen TH, *et al*. Association between p53 and human papilloma virus in head and neck cancer survival. *Cancer Epidem Biomar*. 2008; 17(2): 421-7.
 24. Lin BW, Gong CC, Song HF, Cui YY. Effects of anthocyanins on the prevention and treatment of cancer. *Br J Pharmacol*. 2017; 174(11): 1226-43.
 25. Parawansah, Sudayasa IP, Syarifin ANK, Eso A, Nuralifah, Fathanah WOSR, *et al*. *Momordica charantia* L. fruit fractions inhibit malondialdehyde level and regenerate hepatic damage of hyperglycemic rats. *Indones Biomed J*. 2020; 12(1): 57-61.

ORIGINALITY REPORT

18%

SIMILARITY INDEX

16%

INTERNET SOURCES

9%

PUBLICATIONS

%

STUDENT PAPERS

PRIMARY SOURCES

1

Garuda.Kemdikbud.Go.Id

Internet Source

10%

2

media.neliti.com

Internet Source

1%

3

Valentinus Besin, Abdul Hafid Bajamal, Mohammad Hasan Machfoed, Jusak Nugraha, Budi Utomo, Paulus Budiono Notopuro. "The Effect of Thymoquinone Administration on Local Immunoglobulin-G Levels of Rattus norvegicus Strain Wistar Sciatic Nerve Crush Injury Model", The Indonesian Biomedical Journal, 2022

Publication

1%

4

Bo-Wen Lin, Cheng-Chen Gong, Hai-Fei Song, Ying-Yu Cui. "Effects of anthocyanins on the prevention and treatment of cancer", British Journal of Pharmacology, 2017

Publication

1%

5

Brigitte Rina Aninda Sidharta, Bambang Purwanto, Brian Wasita, Vitri Widyaningsih, Soetrisno Soetrisno. "Single or Divided

1%

Administration of Cisplatin Can Induce Inflammation and Oxidative Stress in Male Sprague-Dawley Rats", The Indonesian Biomedical Journal, 2022

Publication

6	www.inabj.org Internet Source	1 %
7	Djangan Sargowo, Ardian Rizal, Yoga Waranugraha, Anna Fuji Rahimah et al. " β -1,3/1,6-D-glucan of Mycelia Extract Posses Renal Protection Potential and Reduces Nitric Oxide in Obese Subjects", The Indonesian Biomedical Journal, 2022 Publication	1 %
8	cancerpreventionresearch.aacrjournals.org Internet Source	1 %
9	phcogj.com Internet Source	1 %
10	www.journal-jams.org Internet Source	1 %

Exclude quotes On

Exclude matches < 1%

Exclude bibliography On