

# Treatment of bone defects with bovine hydroxyapatite xenograft and platelet rich fibrin (PRF) to accelerate bone healing

*by Rohadi Rohadi*

---

**Submission date:** 25-Apr-2023 11:11PM (UTC-0500)

**Submission ID:** 2075810419

**File name:** B4.pdf (2.09M)

**Word count:** 3921

**Character count:** 22395



Contents lists available at ScienceDirect

## International Journal of Surgery Case Reports

journal homepage: [www.elsevier.com/locate/ijscr](http://www.elsevier.com/locate/ijscr)

Case report



## Treatment of bone defects with bovine hydroxyapatite xenograft and platelet rich fibrin (PRF) to accelerate bone healing

Ahmad Taufik S<sup>a,b,c,\*</sup>, Adnanto Wiweko<sup>a,b</sup>, Didit Yudhanto<sup>a,b,c</sup>, Mohammad Rizki<sup>a,b</sup>, Philip Habib<sup>a</sup>, Bayu Tirta Dirja<sup>a,b</sup>, Rohadi Muhammad Rosyidi<sup>a</sup><sup>a</sup> Faculty of Medicine Mataram University, Indonesia<sup>b</sup> Stem Cell and Regenerative Medicine Center, Mataram University Teaching Hospital, Indonesia<sup>c</sup> Doctorate Program, Faculty of Medicine, Hasanuddin University, Makassar, Indonesia

## ARTICLE INFO

## Keywords:

Bovine hydroxyapatite xenograft  
Platelet-rich fibrin  
Bone defects

## ABSTRACT

**Introduction:** The autograft treatment has become a gold standard therapy for bone defects, although it has its drawbacks and a side effect of donor site morbidity. Furthermore, the bovine hydroxyapatite xenograft due to its excellent osteoconduction characteristic combined with platelet-rich fibrin (PRF), which is a source of growth factor, makes both utilized as therapeutic measures. Therefore, this study examines the potential use of bovine hydroxyapatite xenograft and platelet-rich fibrin in the treatment of bone defects.

**Method:** The report on three cases of bone defects that were treated using a combination of bovine hydroxyapatite xenograft and platelet-rich fibrin (PRF) for internal fixation and grafting was used for this investigation. The study showed that delayed and non-union fractures of the femur, humerus, and tibia may cause bone deformities.

**Result:** The outcome revealed a positive clinical and radiological finding about using the combination of bovine hydroxyapatite xenograft and platelet-rich fibrin (PRF) in the repair of bone defects and acceleration of healing processes.

**Conclusion:** The use of a combination of bovine hydroxyapatite xenograft and platelet-rich fibrin (PRF) in the repair of bone defects shows more effective and accelerated healing. Future studies with a bigger sample size may be carried out and are expected to yield optimal results.

## 1. Introduction and importance

In the discipline of Orthopedics, bone defects are still a major issue. They are characterized by a steady increase in hospitalization, complications, and expense [1]. Additionally, high-energy trauma with bone loss and infection are the most common causes of these defects and if not treated appropriately, bone loss might result in delayed or non-union [2,3]. The incidence of bone abnormalities caused by trauma in Indonesia increases yearly [4]. Therefore, bone grafting which is one of the methods used to address these issues has experienced an increased level of demand [2,4]. The problem of bone defects has also contributed to making bone autograft become the gold standard for treating bone abnormalities, although it has its limitations which are graft quantity and donor site morbidity. Contributory, allografts have become popular for replacing bone defects because the graft size can be easily adjusted but it also has several drawbacks, including disease transfer, rejection reactions, non-union, graft resorption, fracture, and donor restrictions

[3,4].

A xenograft is one of the choices used to overcome these limitations since the raw material is plentiful, readily available, and inexpensive. Additionally, several previous studies showed that organic or inorganic matrix derived from bovine bone is biocompatible, but this biomaterial requires proper preparation to avoid risks such as the transmission of zoonoses [4,5]. Conversely, the addition of an osteoinductive phase to hydroxyapatite has resulted in enhanced stiffness, interconnectivity, and in vitro bioactivity. This scaffold is made entirely of the bone's natural constituent materials, resulting in non-toxic degradation of by-products, high biocompatibility, and the ability to disintegrate in tandem with the creation of new bone in vivo [6].

Platelet Rich Fibrin (PRF) and platelet-rich plasma (PRP) have been thought to promote bone healing because they contain lots of growth factors and cytokines. The use of this fibrin with other bone graft materials has been reported to enhance bone formation. PRF can release growth factors and cytokines, including platelet-derived growth factor

\* Corresponding author at: Jl Majapahit no 62, Mataram, West Nusa Tenggara, Indonesia.

E-mail address: [taufik.unram@gmail.com](mailto:taufik.unram@gmail.com) (A. Taufik S).<https://doi.org/10.1016/j.ijscr.2022.107370>

Received 7 April 2022; Received in revised form 25 June 2022; Accepted 25 June 2022

Available online 29 June 2022

2210-2612/© 2022 The Authors. Published by Elsevier Ltd on behalf of IJS Publishing Group Ltd. This is an open access article under the CC BY-NC-ND license (<http://creativecommons.org/licenses/by-nc-nd/4.0/>).

(PDGF), transforming growth factor  $\beta 1$  and  $\beta 2$  (TGF- $\beta 1$  and  $\beta 2$ ), vascular endothelial growth factor (VEGF), platelet-derived endothelial growth factor, for the promotion of bone healing. The composition of this fibrin is almost the same as PRP but it contains leukocytes and differs in the manufacturing process [7–9].

The use of PRP has become widely accepted in orthopedic, plastic, dental, and oral surgery, either alone or in combination with bone material. This plasma is commonly utilized in the orthopedic sector to treat muscle and tendon wounds, cartilage therapy, and fracture repair [7,8]. Although there hasn't been much coverage of it in bone grafting, particularly for bone defects, its usage in maxillofacial intrabony malformations is extensively documented in this study [9]. Studies on the efficacy of PRF on bone defects are still limited in experimental animals, and clinical studies are also sparse [10].

Therefore, the use of bovine hydroxyapatite xenograft and PRF is expected to provide positive benefits for bone grafting on bone defects. The xenograft of bovine hydroxyapatite is used to build the bony structure. Meanwhile, PRF may aid bone grafting by providing growth factors and cytokines [9,10]. This combination is intended to speed up bone grafting and potentially solve difficulties with bone defect therapy. As a result, the purpose of this study is to report the details of employing both of the materials mentioned. Each case received the necessary consent from both patients and was written in accordance with PRO-CESS guidelines [11]. This report has been registered on Research Registry.com (with the registration number of researchregistry7770).

## 2. Case presentation

The reports of three cases of bone fracture with bone defects were delayed and non-union fractures of these patients were caused by trauma.

### 2.1. First case

A woman, 45 years old with a diagnosed open fracture of the distal humerus and bone loss of 1.5 cm because of a traffic accident. At Mataram University Hospital we perform debridement and internal fixation with plate and screw. Six months later, a patient came to our hospital with a complaint of pain in the distal humerus. Patients lose control because of limited access from home to our hospital. One X-ray examination found delayed union of the distal humerus, minimal callus and loosening of plate and screw (Table 1).

The patient underwent surgery by removing the implant and changes to more stabil internal fixation, freshening fracture and grafting with bovine hydroxyapatite and platelet rich fibrin (PRF). The bovine hydroxyapatite was provided by Dr. Soetomo Hospital Network Bank, which has been standardized by the Indonesian POM while the PRF was prepared according to Doohan standards immediately before surgery [7] (Fig. 1). An evaluation after 6 months found union in the distal humerus on X-ray and achieved a good clinical outcome. No complaints of pain, she can be fully flexed and extended, and has no limitations on doing her daily activities.

**Table 1**  
Case of bone defect and treatment.

No	Case	Treatment
1	Female, 45 y.o. with Delayed union Distal Humerus Fracture + Bone Defects	Internal fixation + Bovine HA + Platelet-rich fibrin (PRF)
2	Female, 25 y.o. with Non-union of Distal Femur fracture + Bone Defects	Internal fixation + Bovine HA + PRF
3	Male, 35 y.o. with Delayed Union of Tibial Fracture + Bone Defects	Internal Fixation + Bovine HA + PRF

### 2.2. Second case

A female is 25 years old with an open comminuted fracture of the distal femur and 2.5 cm of bone loss. The patient underwent debridement and external fixation. After there are no signs of infection, the fixation is replaced with internal fixation nailing (Fig. 2). Ten months later, there were no signs of bone union, minimal callus, and bone defects still found. Then, the patient was operated by adding plates and screws to make the fixation more rigid and grafting with bovine HA and administration of platelet rich fibrin (PRF). On evaluation six months later, it was found that the bones had union on X-ray and achieved a good clinical outcome. The patient can walk without a cane, no complaint of pain, and can be fully flexed and extended.

### 2.3. Third case

Male, 35 years old. Patients come up with complaints of pain in the distal tibia. A clinical examination, we found deformity, no infection. On X-ray we found a delayed union of the distal tibia with a 1.5 cm of bone defect. The patient underwent internal fixation surgery at another hospital seven months earlier. In our hospital, we performed internal fixation with plate and screw and grafting with bovine HA and administration of platelet rich fibrin (PRF).

In the three cases, the healing of bone defects was successful. Patients who previously had delayed and non-union within 6 months were able to achieve union. The radiology examination revealed that the femur and tibia bones were well-aligned and had a union. Clinically, it also produces great outcomes, including the absence of discomfort, adequate joint range of motion, and the capacity to conduct daily activities with no impairment. The postoperative assessment for tibia and femur fractures was based on Kalstrom criteria [12] (Table 2).

## 3. Discussion

In this case, the main treatment is internal fixation, while bovine hydroxyapatite xenograft and the platelet rich (PRF) fibrin are used as adjunctive therapies [2]. Bovine hydroxyapatite is made up of materials which have biological properties that makes it biocompatible and osteoconductive. These important biological properties allow the apposition of newly formed bone by osteoprogenitor cells and the partial remodeling by osteoclast and osteoblast of the host [3]. Hydroxyapatite is used as scaffolds to support the development of bone tissue from an osteoblast proliferation stage through to extracellular matrix (ECM) deposition and on to cell-mediated early-stage mineralization. The addition of small quantities of hydroxyapatite to the scaffolds considerably increases calcium deposition and has a mild osteogenic impact [6].

The transplantation of bone, which stimulates skeletal repair and regeneration, can be influenced by the mechanical environment that can make the procedure multifaceted with several variables determining the rates of success or failure [3,5]. The rejection of a bone graft is one factor that affects graft incorporation. The immunogenicity of allograft and xenograft was investigated, and discovery showed that neither group of bone transplants had a significant increase in Immunoglobulin G. There was also no significant difference in fibrous tissue formation-level between xenograft and allograft in the fourth week [14].

A comparative study was conducted on the effects of bone regeneration between bovine hydroxyapatite combined with freeze-dried platelet-rich plasma (FD-PRP) as a bonegraft in afemoral fracture defect on white rabbits. The study found an elevation in the production of woven bone, osteocalcin, and alkaline phosphatase in the group receiving bovine hydroxyapatite and FD-PRP at the third and sixth-week evaluations. This shows that the combination of these two therapies has contributed to the healing of bone defects [16].

Furthermore, an investigation was carried out on the effects of a bovine-derived xenograft (BDX) and PRP, as well as the combination of

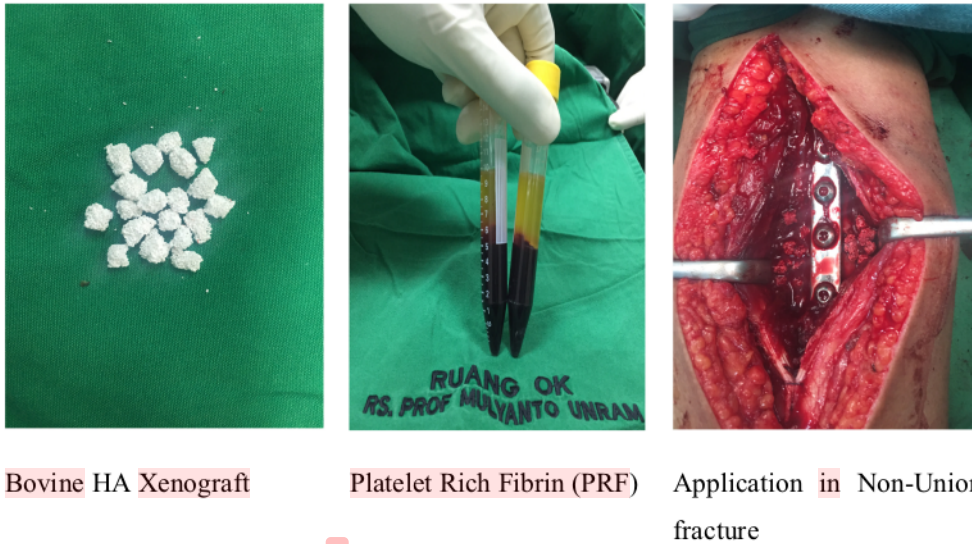


Fig. 1. Application process of bovine Hydroxyapatite (HA) xenograft and Platelet Rich Fibrin (PRF).

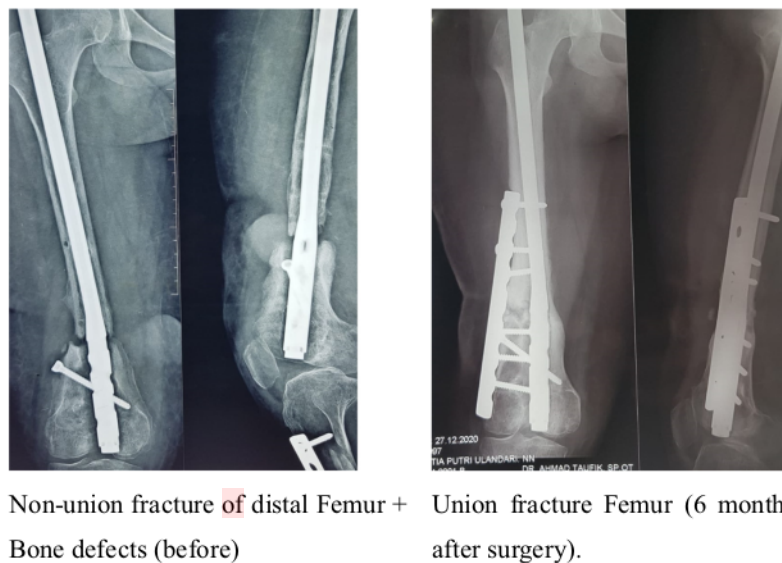


Fig. 2. Radiology of bone fracture with bone defect before and after 6 months surgery.

**Table 2**  
Clinical and radiology outcome after treatment.

No	Case	Outcome (radiology and clinics)
1	Delayed union Distal Humerus Fracture + Bone Defects	Excellent
2	Non-union of Distal Femur fracture + Bone Defects	Good
3	Delayed Union of Tibial Fracture + Bone Defects	Excellent

both, on early wound healing in deep intrabony defects [13]. In this regard, a total of 85 intrabony defects were selected in 20 advanced chronic periodontitis patients. These defects were surgically treated with PRP/BDX and after one year of surgery, the results showed that BDX in combination with PRP lead to a significantly favorable clinical improvement in deep intrabony periodontal defects [13]. There is also a high, statistically significant difference in the percentage of defect resolution in sites treated with hydroxyapatite and PRP as shown by Dawood. Subsequently, this will indicate that PRP is a more beneficial and effective adjuvant to bone transplant in the treatment of periodontal osseous defects [21].

Additionally, PRF either used alone or in combination with an autogenous bone transplant, resulted in accelerated healing of bone



defects, as demonstrated by Kokderen. There were statistically significant differences in osteoblast, new bone area values, and autogenous graft with PRF compared to the other groups [9]. Flowable (injectable) PRF also became an increasingly favored approach for both soft and mineralized tissue healing due to the development of a three-dimensional fibrin network embedding. Nonetheless, this flowable PRF showed similar results with the conventional PRF, but the ease of preparation, application, and manipulation emphasizes its benefits and recommends its application in the implant and bone defects grafting scenarios [19].

The sinus augmentation with freeze-dried Allogenic bone substitute material (ABSM) in combination with injectable PRF, resulted in a reduced healing time before the implant placement as shown by Solomia. Furthermore, the addition of PRF to ABSM has been shown to enhance bone maturation and shorten the period before implant placement. This could be explained by the (minimal) osteoinductive potential of ABSM which may be further enhanced by platelet concentrates cellular components, and could be used to compare its induction characteristics to autologous bone transplants, opening up new avenues for bone regeneration [10].

The combination of bovine hydroxyapatite xenograft and PRF fulfill the requirements for the promotion of bone regeneration. This PRF contains leukocytes that regulate immunological responses, anti-infectious activities, and matrix remodeling during wound and bone healing through the release of growth factors [18]. The bovine hydroxyapatite xenograft would serve as a scaffold to osteoconduction while the PRF serves as a growth factor that allows bone healing. Similarly, Anorganic Bovine Bone Mineral (ABBM) and its combination with PRF can effectively treat intra-bony defects in the maxillofacial region as discovered by Yosemin [18]. Additionally, the combination of Demineralized Freeze-Dried Bone Allograft (DFDBA) and PRF showed improved clinical and radiographic parameters. Furthermore, this combination produced a synergistic effect for treating intrabony defects in chronic periodontitis patients [17].

A study was conducted by Djarni and Siswanto on the effects of PRF and bone graft in the treatment of intrabony defects, using a total of 4 studies for inclusion with 107 patients as subjects. The result of this study showed that utilizing bone graft as a single therapy produced better outcomes than using this fibrin alone or in combination with bone graft [21]. It was also discovered that PRF and DFDBA provided superior outcomes than the standard technique. Additionally, because this fibrin is made from the patient's blood, it has a lower risk of allergic responses, is easily available, and is cost-effective [18].

However, there are contradictory reports on the biological influence of PRP on bone healing enhancement. The combination of PRP with autogenous bone did not improve the bone healing process in rabbits with calvarial defects utilizing an autogenous graft with or without the plasma as shown by studies [24]. In rabbits with calvarial defects, an examination was carried out on the influence of PRF on bone regeneration of different grafting materials. It was also shown that PRF improved bone production when administered alone or in combination with autogenous bone, but not when paired with deproteinized bovine bone [22].

In another study that examined the relationship between PRF and Bio-Os in the rat calvarium, this fibrin showed a synergistic effect with Bio-Os. According to the results, the autogenous graft-PRF combination was more effective than another xenograft group, but the results were statistically insignificant [23]. In terms of new bone formation, autograft combined with the fibrin yielded superior results but its combination with Beta tricalcium phosphate (b-TCP) had no effect compared to the only b-TCP group. However, further experimental and clinical studies may be beneficial in clarifying the exact mechanism and results of combining this fibrin with bone grafts on the bone healing process [22].

#### 4. Conclusion

The combination of bovine hydroxyapatite xenograft and platelet-rich fibrin (PRF) on the treatment of bone defects led to the achievement of outstanding results with good radiological and clinical backings. This treatment modality may offer new hope for the healing of bone defects. Furthermore, future research with larger sample size is required to strengthen the optimism of the results.

#### Funding

This research did not receive any specific grant from funding agencies in the public, commercial, or not-for-profit sectors.

#### Consent

All patients in this report have been informed regarding the report and its publication. All patients have signed written consent.

#### Provenance and peer review

Not commissioned, externally peer-reviewed.

#### Ethical approval

This study has been reviewed and approved by the authors' Institutional Review Board.

#### Author contribution

Ahmad Taufik S: conceptualization, writing original draft preparation, supervision, project administrator, validation.

Adnanto wiweko: data collecting, data interpretation, writing original draft preparation, writing the paper and editing, validation.

Didit Yudhanto: data collecting, data interpretation, writing original draft preparation.

Muhaammad Rizki: data collecting, data interpretation, writing original draft preparation, writing the paper and editing, validation.

Philip Habib: data collecting, data interpretation, writing the paper and editing, validation, proof-reading.

Bayu Tirta Dirja: Data interpretation, writing the paper and editing, validation, review Manuscript, proof-reading.

Rohadi Muhamad Rosyidi: Data interpretation, writing the paper and editing, validation, review Manuscript, proof-reading.

#### Registration of research studies

We have registered our case series in "Research Registry" with registration number of "researchregistry7770".

#### Guarantor

Ahmad Taufik S.

#### Declaration of competing interest

We declare that they have no known competing financial interests or personal relationships that could have appeared to influence the work reported in this paper.

#### Acknowledgements

We acknowledge the support in preparation of the bovine Xenograft to Tissue Bank of Dr. Soetomo General Hospital, Faculty of Medicine, Universitas Airlangga, Surabaya, East Java, Indonesia.

We also acknowledge the support and assistance in preparation of

PRF to all personnel of Stem Cell and regenerative medicine Centre, Mataram University Hospital, University of Mataram, Indonesia.

## References

- [1] Andrea Wiese, C. Hans, Pape bone defects caused by high-energy injuries, bone loss, infected nonunions, and nonunions, *Orthop. Clin. N. Am.* 41 (2010) 1–4.
- [2] J.F. Keating, Simpson AHRW, C.M. Robinson, The management of fractures with bone loss, *The Journal Of Bone And Joint Surgery* 87-B (2) (2005). March.
- [3] A.S. Brydone, D. Meek, S. MacLaine, Bone grafting, orthopedic biomaterials, and the clinical need for bone engineering, *Proc. Inst. Mech. Eng. H J. Eng. Med.* 224 (12) (2010) 1329–1343.
- [4] M. Ferdiansyah, N.U. Dwikora, S. Heri, W.M. Tri, E. Mouli, L.G. Imelda, Comparative effectiveness of bone grafting using xenograft freeze-dried cortical bovine, allograft freeze-dried cortical New Zealand white rabbit, xenograft hydroxyapatite bovine, and xenograft demineralized bone matrix bovine in bone defect of femoral diaphysis of white rabbit: experimental study in vivo, *Int. J. Biomater.* (2017) 9, <https://doi.org/10.1155/2017/7571523>, 7571523.
- [5] G.P. Greitel, M.S. Macarena, Ricardo Orzuza Gonzalez-Chaves, N.Z. Susana, Preliminary study on the biocompatibility and osteoconductive properties of a new bovine bone graft, *Actual Osteol.* 13 (2) (2017) 116–124.
- [6] J.P. Gleeson, N.A. Plunkett, F.J. O'Brien, Addition of hydroxyapatite improves stiffness, interconnectivity, and osteogenic potential of a highly porous collagen-based scaffold for bone tissue regeneration, *Eur. Cell. Mater.* 20 (2010) 218–230.
- [7] S. Barbon, E. Stocco, V. Macchi, M. Contran, F. Grandi, A. Borean, P. Pamigotto, A. Porzionato, R.D. Caro, Platelet-rich fibrin scaffold for cartilage and tendon regenerative medicine: from bench to bedside, *Int. J. Mol. Sci.* 20 (2019) 1701.
- [8] Wang Peng, Hyun-young Cho, Ji-Hoon Seo, Dong-Hwan Lee, Jun-Min Jang, Seung-Hoon Park, Il-Kyu Kim, The healing effect of platelet-rich plasma on xenograft in peri-implant bone defects in rabbits, *Maxillofacial Plastic and Reconstructive Surgery* 38 (2016) 16.
- [9] N.K. Nesligül, B. Timuçin, F. Yavuz, The use of platelet-rich fibrin (PRF) and PRF-mixed particulate autogenous bone graft in the treatment of bone defects: an experimental and histomorphometrical study, *Dental Research Journal* 12 (5) (2015). September.
- [10] K. Solomiya, B. Sebastian, P. Andreas, T. Daniel, Bilal Al-Nawasand Peer W. Kämmerer, Combination of an allogenic and a xenogenic bone substitute material with injectable platelet-rich fibrin – A comparative in vitro study, *Journal of Biomaterials Applications* (2020) 1–14, 0(0).
- [11] R.A. Agha, T. Franchi, C. Sohrabi, G. Mathew, for the SCARE Group, The SCARE 2020 guideline: updating consensus Surgical CAse REport (SCARE) guidelines, *International Journal of Surgery* 84 (2020) 226–230.
- [12] Alaa M. Hegazy, Surgical management of ipsilateral fracture of the femur and tibia in adults (the floating Knee): postoperative clinical, radiological, and functional outcomes, *ClinicsOrthopedic Surgery* 3 (2011) 133–139.
- [13] S. Yilmaz, G. Cakar, B. Kuru, Platelet-rich plasma in combination with bovine derived xenograft in the treatment of deep intrabony periodontal defects: a report of 20 consecutively treated patients, *Platelets* 20 (2009) 432–440.
- [14] Ferdiansyah, N.U. Dwikora, S. Heri, L.G. Imelda, Immunogenicity of bone graft using xenograft freeze-dried cortical bovine, allograft freeze-dried cortical New Zealand white rabbit, xenograft hydroxyapatite bovine, and xenograft demineralized bone matrix bovine in bone defect of femoral diaphysis white rabbit experimental study in vivo, in: *The Veterinary Medicine International Conference*, 2017.
- [15] A. Abhinav, R.G. Jagadish, Vikram R. Guntakandla, K.P. Sunil, D. Satyanarayana, P. Rajababu, Clinical and radiographic evaluation of platelet-rich fibrin as an adjunct to bone grafting demineralized freeze-dried bone allograft in intrabony defects, *J. Indian Soc. Periodontol.* 24 (2020) 60–66.
- [16] K.P. Renjith, V.V. Harish Kumar, V.C. Santhosh, Sreekanth Puthalath, Shabeer Mohamed, Platelet rich fibrin (PRF) and bonegraft-magical tools in periodontics- a case report, *International Journal of Periodontology and Implantology* 2 (1) (2017) 23–26. January-March.
- [17] S. Yasemin, U. Ahu, I. Levent Taner, Rana ÇulhaoğLu, Effects of platelet-rich fibrin on healing of intra-bony defects treated with anorganic bovine bone mineral, *Braz. Oral Res.* 31 (1) (2017), e15.
- [18] S Hesham T Abdelmoneimand Radwa Elsharkawy n.d. Flowable platelet rich fibrin a new trend for enhancing bone augmentation results in maxillary sinus floor augmentation (radiographic and histologic evaluation). *Egypt. Dent. J.* ; 66(2).
- [19] I. Arni, Heri Siswanto Djais, A comparative study of platelet-rich fibrin and bone graft in intrabony defect treatment: A systematic review, *J. Dentomaxillofac. Science* 5 (3) (December 2020) 137–140.
- [20] K. Fatih, T.K. Ela, N. Yusuf, Neslihan Coşkun Akçay Selçuk T. Bema, K. Ersöz, U. Ersin, Combining platelet-rich fibrin with different bone graft materials: An experimental study on the histopathological and immunohistochemical aspects of bone healing, *Journal of Cranio-Maxillo-Facial Surgery* 47 (2019), 815e825.
- [21] MR Oliveira A. de C Ferreira S Silva CC Avelino IR Garcia Jr. RC Mariano n.d. Influence of the association between platelet-rich fibrin and bovine bone on bone regeneration. A histomorphometric study in the calvaria of rats.
- [22] P. Prisana, N. Thongchai, V. Surapong, P. Kingkaew, The primacy of platelet-rich fibrin on bone regeneration of various grafts in rabbit's calvarial defects, *J. Craniomaxillofac. Surg.* 41 (2013) e191ee200.

# Treatment of bone defects with bovine hydroxyapatite xenograft and platelet rich fibrin (PRF) to accelerate bone healing

## ORIGINALITY REPORT

20%

SIMILARITY INDEX

21%

INTERNET SOURCES

11%

PUBLICATIONS

%

STUDENT PAPERS

## PRIMARY SOURCES

1

[www.researchgate.net](http://www.researchgate.net)

Internet Source

15%

2

[jkamprs.springeropen.com](http://jkamprs.springeropen.com)

Internet Source

3%

3

[repository.unair.ac.id](http://repository.unair.ac.id)

Internet Source

3%

Exclude quotes On

Exclude matches < 3%

Exclude bibliography On

# Treatment of bone defects with bovine hydroxyapatite xenograft and platelet rich fibrin (PRF) to accelerate bone healing

---

## GRADEMARK REPORT

---

FINAL GRADE

**/0**

GENERAL COMMENTS

**Instructor**

---

PAGE 1

---

PAGE 2

---

PAGE 3

---

PAGE 4

---

PAGE 5

---