

## Effects of misoprostol as a drug to induce abortion in the second trimester: a forensic case report



Arfi Syamsun<sup>1\*</sup>, Jaury Sutjiyanto<sup>1</sup>, Elita Rahma<sup>1</sup>, Rina Masadah<sup>2</sup>,  
Husni Cangara<sup>2</sup>, Berti Julian Nelwan<sup>2</sup>

### ABSTRACT

**Introduction:** Induced abortion with misoprostol in the second trimester can be harmful to both mother and fetus, especially when the abortion is self-administered with telemedicine. Considering the effects that might occur in misoprostol usage to induce abortion, we ought to present our experience through this article regarding the effect of misoprostol as a drug to induce abortion in the second trimester.

**Case Description:** In the first case, a 30-year-old woman engaged in a self-induced abortion at her residence subsequent to consulting with medical personnel at a local community health centre, where she received oral and vaginal administration of misoprostol. Unfortunately, complications arose as the mother experienced post-abortion bleeding, which necessitated a curative procedure. Tragically, the fetus perished in utero due to asphyxia. In the second case, a 20-year-old woman opted to undergo a self-induced abortion at home following consultation and the acquisition of misoprostol from an online source. In cases where fetuses experience asphyxia within the womb, they are unable to exit the uterus spontaneously. Consequently, the mother experienced post-abortion bleeding as an aftermath of the procedure.

**Conclusions:** Misoprostol-induced abortion in the second trimester causes maternal bleeding and intrauterine fetal mortality. Medical staff should handle abortions professionally, considering into account both the patient's health and the legal considerations.

**Keywords:** Induced abortion, misoprostol, telemedicine, second trimester.

**Cite This Article:** Syamsun, A., Sutjiyanto, J., Rahma, E., Masadah, R., Cangara, H., Nelwan, B.J. 2023. Effects of misoprostol as a drug to induce abortion in the second trimester: a forensic case report. *Bali Medical Journal* 12(2): 2050-2054. DOI: 10.15562/bmj.v12i2.4509

<sup>1</sup>Forensic and Medicolegal Department,  
Faculty of Medicine, Universitas  
Mataram, Mataram Indonesia, 83125;

<sup>2</sup>Pathology Anatomy Department,  
Faculty of Medicine, Universitas  
Hasanuddin, Makassar Indonesia, 90245.

\*Corresponding author:

Arfi Syamsun;  
Forensic Department, Faculty of  
Medicine, Universitas Mataram,  
Mataram Indonesia, 83125;  
arfisyamsun@unram.ac.id

Received: 2023-04-24

Accepted: 2023-06-03

Published: 2023-06-25

### INTRODUCTION

Abortion, whether spontaneous or induced, is a common pregnancy problem. According to the World Health Organization, around 79 million unwanted pregnancies, excluding miscarriages, occur globally yearly.<sup>1</sup> In addition, around 46 million induced abortions occur worldwide each year.<sup>2</sup> Estimating the overall number of abortions is difficult, particularly in poor countries, and it is sometimes underreported owing to legislative constraints. A large percentage of abortions are done in unsanitary conditions. Abortion may impose an unfavorable cost on families and the healthcare system. After abortions that are not performed under medical supervision, serious consequences such as maternal mortality, uterine rupture, and infection may ensue.<sup>3</sup> The procedure's

safety is critical in producing a non-life-threatening outcome.

Induced abortions can be performed using medical and surgical procedures. Medical abortion is the use of particular drugs to induce early abortion, and it is considered effective if it is completed without the need for surgical intervention. Furthermore, with high patient satisfaction, the therapeutic approach is a safe and effective alternative to surgical treatment.<sup>4</sup>

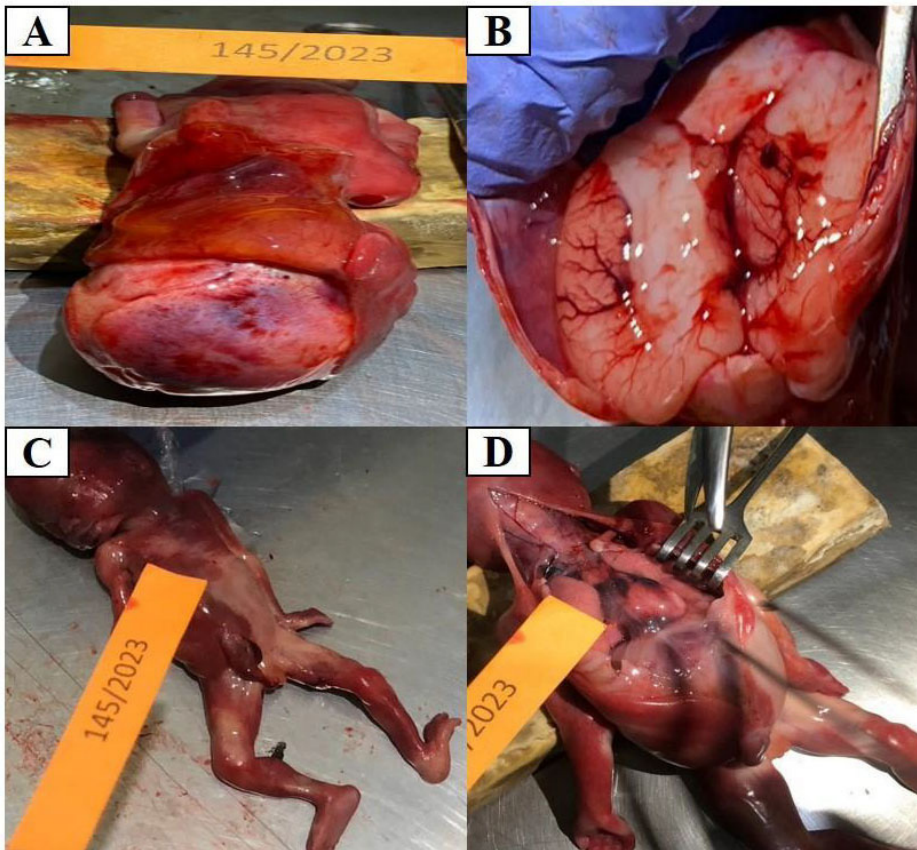
Misoprostol is a synthetic prostaglandin E1 analog used to prevent stomach ulcers, manage spontaneous abortions, and induce abortions.<sup>4,5</sup> This medication is a safe and successful medical approach for terminating a pregnancy in the second trimester.<sup>4,6</sup> Misoprostol is a uterotonic that promotes uterine smooth muscle contraction and cervical dilatation. However, problems including uterine

rupture, clotting abnormalities, and severe, abnormal vaginal bleeding are conceivable. Misoprostol usage and dose for second-trimester pregnancy termination in women with a history of cesarean section have also been considered.<sup>6</sup>

Considering the effects that might occur in misoprostol usage to induce abortion, we ought to present our experience through this article regarding the effects of the misoprostol as a drug to induce abortion in the second trimester.

### CASE

**Case 1.** A 30-year-old woman who was 4-5 months pregnant came to consult with a midwife for an abortion. The midwife administered a therapy of 2 tablets of misoprostol to be taken orally and 1 tablet of medication to be inserted into the vagina. Several hours after taking the



**Figure 1.** A) Bruises on the head muscles; B) Dilatation of cerebral blood vessels and blood clots in the brain stem; C) Multiple bruises on the head, neck, chest, shoulders, hands, thighs, calves, and feet; D) Multiple bruises in the chest muscles, neck muscles, and pericardium.

drug, the patient experienced abdominal cramps. After approximately 12 hours, the baby was spontaneously delivered in a condition where it had already passed away. Autopsy findings revealed that the fetus was non-viable, weighing 300 grams and 23 cm long. The baby passed away before the entire body was outside the genital area. Signs of asphyxia were also found, including dilated blood vessels in the brain, darker-colored blood, and blood clots in the heart cavity and the brainstem. Additionally, bruising injuries were found on the hands and feet.

**Case 2.** A 20-year-old woman who was approximately 4-5 months pregnant consumed misoprostol pills she purchased online. After taking 2 tablets orally and inserting 1 tablet vaginally, she experienced abdominal cramps and went to the hospital's emergency department. Medical personnel found that her cervix was dilated by 3 cm, and the baby was still alive, with the buttocks visible at the cervix.

The medical team performed a breech delivery as the mother continued to push and wanted to deliver. Autopsy results revealed a non-viable fetus weighing 450 grams and measuring 25 cm in length. The baby passed away before the entire body was outside the genital area. Signs of asphyxia were also found, including dilated blood vessels in the brain, darker-colored blood, and the absence of blood clots in the heart cavity. Additionally, bruising injuries were found on the neck, hands, buttocks, and feet.

## DISCUSSION

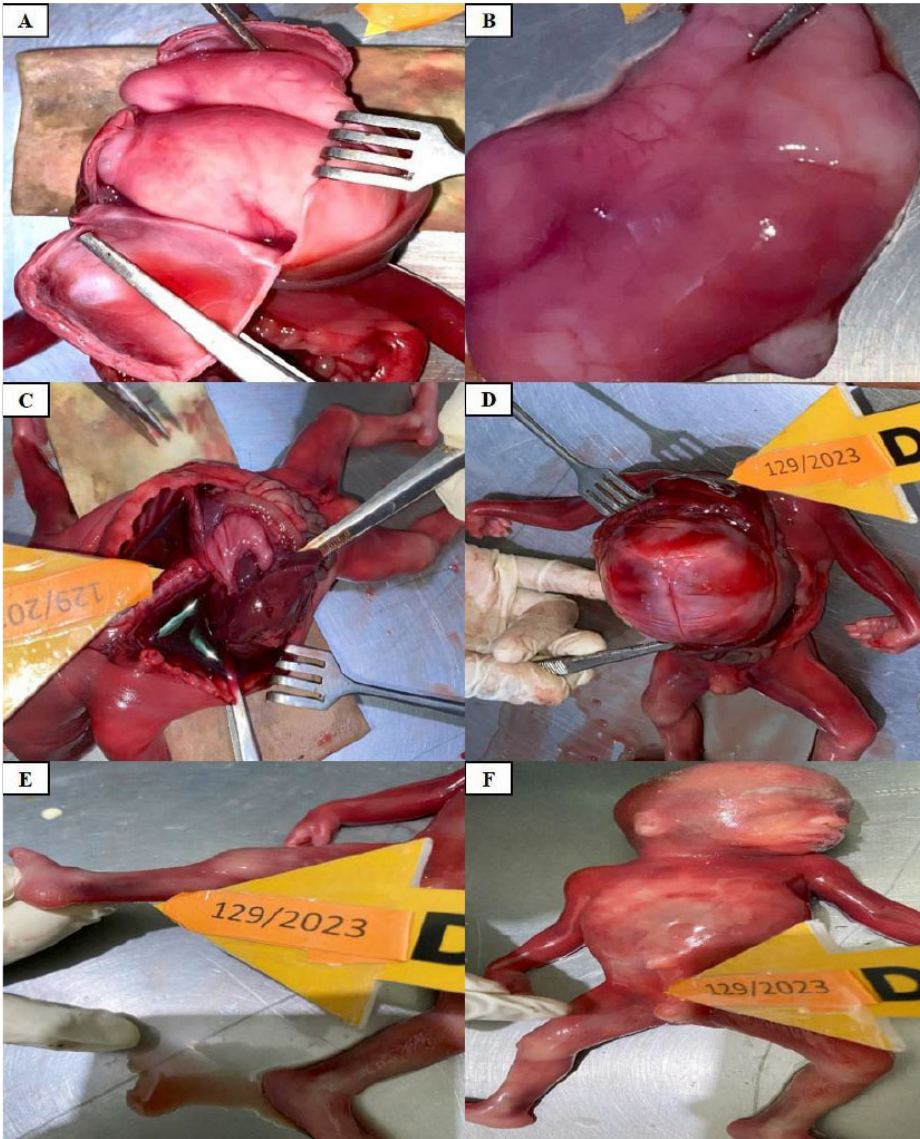
Abortion is one of the medical procedures recommended by the World Health Organization (WHO) that can be provided at the lowest level of the healthcare system. Therefore, efforts to train healthcare providers at the mid-level, such as midwives, nurses, and other non-doctor healthcare providers, in safe abortion methods are crucial. Patients require access

to secure abortion healthcare services, which can be provided by healthcare professionals at primary healthcare facilities, utilizing both medication and surgical interventions. There is no statistically significant difference in the risk of complications for first-trimester surgical abortions performed by mid-level providers compared to doctors.<sup>7</sup>

Early medical abortion in the first trimester performed in primary care is a safe, cost-effective, and acceptable alternative. This medical procedure can be carried out by general practitioners who have completed abortion training. Abortion can be induced using mifepristone and misoprostol up to nine weeks of gestation. Contraindications for this type of abortion include anticoagulant use and severe anemia. Patients should be provided with information regarding the expected effects of the medication, possible side effects, and complications associated with the drug. The woman should be aware of when to seek emergency care.<sup>8</sup> Healthcare providers who offer abortion services and treatment for abortion complications require training on the proper use of misoprostol and the management of complications. Women and pharmacy personnel also need this information. Legal and policy reforms are necessary to enable the training and provision of safe abortion services. Further research is required to understand the extent and impact of improper administration of misoprostol.<sup>9</sup>

Induced abortion using the drug misoprostol has been widely reported. The use of misoprostol for abortion purposes in Brazil has been carried out since the late 1980s. The drug began to be used for self-induced abortions when it started to be commercialized for treating stomach ulcers. Most women who undergo abortions are still young and do so before 15 weeks of pregnancy. The rate of misoprostol usage ranges from 89% to 36%. The drug is effective in terminating pregnancies in the first trimester and has a low rate of complications.<sup>10</sup> Medical abortion in the first trimester has shown successful outcomes, whether the medication is taken at a healthcare facility or home.<sup>11</sup> Home administration of misoprostol is an effective and acceptable





**Figure 2.** A) Blood vessel dilation in the brain (a); B) Blood vessel dilation in the brain (b); C) Watery and blackish-colored blood; D) Haemorrhage of the head muscles; E) Bruises of the calf and ankle; F) Bruises on the thighs and chest.

method for abortion up to 63 days of gestation. Misoprostol itself is effective and safe, making it a reasonable choice for women seeking abortion in the first trimester.<sup>12</sup>

The intravaginal administration of misoprostol significantly contributes to managing intrauterine fetal death in Brazilian primary health centers. Therefore, the availability of this medication is recommended in Brazil.<sup>13</sup> All respondents have previously undergone abortions to limit their fertility. All women specifically requested misoprostol within a few days of their pregnancies, indicating that they knew about misoprostol as a

backup in case of contraceptive failure and may have also planned to use misoprostol as a contraceptive substitute.<sup>14</sup> In case 1, the patient received information on using misoprostol for abortion from healthcare providers at the primary healthcare facility. Whereas in case 2, the patient obtained information on misoprostol from telemedicine services, which have seen significant development in Indonesia in recent years.

Medicinal abortion is justified under the applicable Health Law in Indonesia. Based on Article 75, any person is prohibited from performing an abortion, except in cases of medical emergencies

detected early in pregnancy that threaten the life of the mother and the fetus. These medical emergencies include severe genetic diseases or irreversible congenital disabilities that would make it difficult for the baby to survive outside the womb and pregnancies resulting from rape that can cause psychological trauma to the rape victim. Medical procedures can only be carried out after pre-procedure counseling and concluded with post-procedure counseling provided by qualified and authorized counselors. Furthermore, Article 76 explains that abortions, as referred to in Article 75, can only be performed before the pregnancy reaches 6 (six) weeks from the last menstrual period, except in cases of medical emergencies where the abortion is performed by healthcare professionals who possess the skills and qualifications certified by the Minister. The abortion procedure must have the consent of the pregnant mother, except in cases of rape victims, and the process must be carried out in healthcare facilities that meet the requirements established by the Minister.<sup>15</sup> According to the law in Indonesia, the discussed case has violated legal norms: abortion performed beyond 6 weeks of gestation, not conducted in a healthcare facility with comprehensive medical facilities, and not performed by trained healthcare professionals. Therefore, this woman may be subject to imprisonment as a consequence.

Self-induced abortions by women will continue to increase when there are barriers to safe abortion services, such as restrictive laws, a lack of financial resources, and limited access to healthcare facilities. One way to limit self-induced abortions is by reducing financial barriers, improving access to healthcare facilities, removing legal restrictions on abortion, and eliminating telehealth restrictions for abortion. These measures can help reduce the prevalence of self-induced abortions.<sup>16</sup> Certain medical procedures, such as abortion, are not universally embraced within religious legal frameworks, thus generating a prevailing social stigma within local communities and beyond. Opposition to abortion is primarily rooted in religious beliefs, which form the foundation for

disapproval. In conservative religious societies, the acceptance of even modern legislation about medical abortion proves challenging, resulting in societal discord between abortion providers, healthcare practitioners, and the community.<sup>17</sup>

The toxicological examination of the mother's blood (collected two days after the termination of pregnancy) did not show the presence of abortifacient substances. Forensic toxicology examinations were conducted on three different biological samples (whole blood, placenta, and fetal liver) using the UHPLC-QqQ-MS/MS method. The validation parameters of this method are as follows: detection limit: 25 pg/mL; quantification limit: 50 pg/mL.<sup>18</sup> Information regarding the use of misoprostol, in this case, was obtained from the crime scene investigation conducted by the police and the investigation of digital traces, including online orders and purchases of misoprostol. A misoprostol examination was not performed during the autopsy because the woman and other witnesses, such as the midwife and her boyfriend, were admitted to the administration of misoprostol for abortion. According to criminal acts in Indonesia, the quality of this evidence falls under the categories of clues, witness statements, and defendant statements.

Misoprostol effectively induces abortion in 248 cases (98.0%) that required an average of 1468.8 mg and an average induction time of 2.3 days. Analysis of the distribution of the total dose of misoprostol needed for fetal expulsion did not show significant variation based on increasing gestational age. Therefore, the misoprostol protocol used is effective and safe for second-trimester abortions in pregnancies resulting from sexual violence.<sup>19</sup>

Misoprostol is a synthetic prostaglandin E1 commonly used to induce abortion. There is limited literature on the cardiovascular side effects of misoprostol, but there is evidence of side effects such as heart attacks due to coronary vasospasm. Therefore, it is necessary to prepare a medication to anticipate such incidents, such as intra-arterial nitroglycerin.<sup>12</sup> In a study conducted in Brazil, few cases with side effects were found, such as immediate excessive uterine bleeding after

expulsion (2.6%), which can be controlled through standard procedures to enhance uterine contractions and complementary evacuation through curettage without the need for blood transfusion (1.6%). In comparison, some cases required blood transfusion (1.2%). No other complications were identified apart from the side effect of bleeding.<sup>19</sup> In cases 1 and 2, the side effect observed was bleeding. The bleeding experienced by the woman in case 1 was due to the retained placenta, requiring a medical procedure called curettage. On the other hand, the bleeding experienced by the woman in case 2 was severe enough to require blood transfusion treatment at the hospital. More severe side effects are likely due to the advanced gestational age in the second trimester, where the fetus has grown larger and has a strong attachment to the uterus.

In general, complications of unsafe abortions primarily include uterine bleeding, septicemia, and peritonitis. Between 20% and 30% of unsafe abortions result in infection, and between 20% and 40% of cases have severe pelvic conditions. The risk of death associated with unsafe abortions varies across different regions. The abortion-related mortality rate is 460 per 100,000 procedures in Africa overall and 520 per 100,000 in the sub-Saharan area. In Asia, it is 160 per 100,000, and in Latin America, it is 30 per 100,000.<sup>20</sup>

The administration of a single dose of misoprostol in the vagina can induce uterine contractions, followed by an increase in uterine tone. After 1-2 hours, uterine contractions become regular and can last up to 4 hours after administration. Misoprostol has been widely used to soften the cervix before labor induction and surgical evacuation of the uterus. Mutagenicity studies on misoprostol have not demonstrated embryotoxic, fetotoxic, or teratogenic effects. Therefore, these malformations may be caused by the insufficient blood supply to the developing embryo during contractions induced by misoprostol.<sup>21</sup>

Telemedicine is the remote assessment and treatment of patients using telecommunications technology. In abortion care, telemedicine services may be used for counseling and review, acquiring abortion medication, and

clinical guidance through the abortion process.<sup>22</sup> Because of legal abortion restrictions, stigma, fear, clinician shortages in many medical specialties and limited resources have increased the use of telemedicine.<sup>23</sup> Telemedicine has proven safe, feasible, effective, and acceptable in the US, especially during the COVID-19 pandemic. Telemedicine for medical abortion was found to be effective, secure, and good, and it increased access to abortion care even in the absence of a pregnancy test and ultrasound.<sup>24</sup> In case 2, the patient purchased the abortion drug misoprostol online after she found information about medical abortion on online consultation media. She went to the hospital after thinking the abortion had failed to expel the fetus. The medical staff then removed the fetus and treated the patient's bleeding.

## CONCLUSION

Induced abortion with misoprostol in a second-trimester pregnancy causes maternal bleeding and causes intrauterine fetal death. Medical personnel should be professional in handling abortions by considering the health aspects of the patient and the legal aspects.

## ETHICAL CONSIDERATION

This case report has received informed consent from the patient. This study has been approved by the Ethical Committee for Medical Research Faculty of Medicine, the University of Mataram No. 211/UN18.F8/ETIK/2023.

## FUNDING

No specific funding was received for this study.

## CONFLICT OF INTEREST

No potential conflict of interest relevant to this article was reported.

## AUTHOR CONTRIBUTION

AS responsible for concepts, design, definition of intellectual content, literature search, clinical studies, data acquisition, data analysis, manuscript preparation, manuscript editing, manuscript review,



and guarantor of the study. JS and ER responsible for definition of intellectual content, literature search, clinical studies, data acquisition, data analysis, manuscript preparation, manuscript editing, manuscript review, and guarantor of the study. RM responsible for concepts, design, clinical studies, data analysis, manuscript preparation, manuscript editing, manuscript review, and guarantor of the study.

## REFERENCES

- Sedgh G, Bankole A, Oye-Adeniran B, Adewole IF, Singh S, Hussain R. Unwanted pregnancy and associated factors among Nigerian women. *Int Fam Plan Perspect.* 2006;32(4):175–84. DOI: <https://doi.org/10.1363/3217506>.
- Sedgh G, Henshaw S, Singh S, Åhman E, Shah IH. Induced abortion: estimated rates and trends worldwide. *Lancet.* 2007;370(9595):1338–45. DOI: [https://doi.org/10.1016/s0140-6736\(07\)61575-x](https://doi.org/10.1016/s0140-6736(07)61575-x).
- Shaikh Z, Abbasi RM, Rizwan N, Abbasi S. Morbidity and mortality due to unsafe abortion in Pakistan. *Int J Gynecol Obstet.* 2010;110(1):47–9. DOI: <http://dx.doi.org/10.1016/j.ijgo.2010.01.028>
- Walters KM, Simon RA, Woessner KM, Wineinger NE, White AA. Effect of misoprostol on patients with aspirin-exacerbated respiratory disease undergoing aspirin challenge and desensitization. *Ann Allergy, Asthma Immunol.* 2017;119(1):71–6. DOI: <http://dx.doi.org/10.1016/j.anai.2017.05.003>
- Kurniawan RH, Cahya NP. Potentially acute misoprostol toxicity during third-trimester pregnancy: a case report. 2023;12(1):606–8. DOI: <http://dx.doi.org/10.15562/bmj.v12i1.3873>.
- Stephenson ML, Wing DA. Misoprostol for induction of labor. *Semin Perinatol.* 2015;39(6):459–62. DOI: <http://dx.doi.org/10.1053/j.semperi.2015.07.008>
- Barnard S, Kim C, Park MH, Ngo TD. Doctors or mid-level providers for abortion. *Cochrane Database Syst Rev.* 2014;2014(7). DOI: <https://doi.org/10.1002/14651858.cd011242.pub2>.
- Bateson D, McNamee K, Harvey C. Medical abortion in primary care. *Aust Prescr.* 2021;44(6):187–92. DOI: <https://doi.org/10.18773/austprescr.2021.050>.
- Pourette D, Mattern C, Ratovoson R, Raharimalala P. Complications with use of misoprostol for abortion in Madagascar: between ease of access and lack of information. *Contraception.* 2018;97(2):116–21. DOI: <https://doi.org/10.1016/j.contraception.2017.12.005>.
- Machado LO, Taquette SR. The use of misoprostol in the termination of pregnancy: a review of studies carried out. *Cienc e Saude Coletiva.* 2022;27(8):3079–90. DOI: <https://doi.org/10.1590/1413-81232022278.03102022>.
- Kapp N, Eckersberger E, Lavelanet A, Rodriguez MI. Medical abortion in the late first trimester: a systematic review. *Contraception.* 2019;99(2):77–86. DOI: <https://doi.org/10.1016/j.contraception.2018.11.002>
- Jamali M, Bakhtiyari M, Arab F, Mirzamoradi M. Misoprostol complications in second-trimester termination of pregnancy among women with a history of more than one cesarean section. *Obstet Gynecol Sci.* 2020;63(3):323–9. DOI: <https://doi.org/10.5468/ogs.2020.63.3.323>.
- Nascimento MI Do, Cunha ADA, Oliveira SRDSM, Nunes GG, Alvarez FS, Villas Bôas EL. Misoprostol use under normal conditions for termination of pregnancies with intrauterine fetal death. *Rev Assoc Med Bras.* 2013;59(4):354–9. DOI: <http://dx.doi.org/10.1016/j.ramb.2013.02.005>
- Chahal H, Mumtaz Z. Abortion and fertility control in Pakistan: The role of misoprostol. *J Fam Plan Reprod Heal Care.* 2017;43(4):274–80. DOI: <https://doi.org/10.1136/jfprhc-2015-101424>.
- Kementrian Kesehatan. Undang-Undang Kesehatan. 2009;
- Upadhyay UD, Cartwright AF, Grossman D. Barriers to abortion care and incidence of attempted self-managed abortion among individuals searching Google for abortion care: A national prospective study. *Contraception.* 2022;106:49–56. DOI: <https://doi.org/10.1016/j.contraception.2021.09.009>
- Syamsun A, Kadriyan H, Lestari NPS, Lestari IA, Rivarti AW, Bukhari A, et al. The role of the rapid molecular test (RMT) and the provision of a negative pressure mortuary room in reducing COVID-19 corpse handling protocol rejection: experiences with religious conservative groups. *Egypt J Forensic Sci.* 2022;12(1). DOI: <https://doi.org/10.1186/s41935-022-00267-5>
- Szpot P, Wachelko O, Zawadzki M. Forensic Toxicological Aspects of Misoprostol Use in Pharmacological Abortions. *Molecules.* 2022;27(19):1–14. DOI: <https://doi.org/10.3390/molecules27196534>.
- Drezett J, Bessa MMM, Pedroso D, Fernandes Silva AC, Gebrim LH, De Vasconcellos RM, et al. Misoprostol for induction of second trimester abortion in pregnancies resulting from sexual violence: Effectiveness analysis of a protocol applied in the Brazilian public health service. *Reprod e Clim.* 2014;29(3):105–11. DOI: <http://dx.doi.org/10.1016/j.recli.2015.04.001>
- WHO. Information sheet Safe and unsafe induced abortion Global and regional levels in 2008, and trends during 1995 – 2008 Information sheet. *Inf Sheet.* 2008;1–8.
- Tang OS, Gemzell-Danielsson K, Ho PC. Misoprostol: Pharmacokinetic profiles, effects on the uterus and side-effects. *Int J Gynecol Obstet.* 2007;99(SUPPL. 2):160–7. DOI: <https://doi.org/10.1016/j.ijgo.2007.09.004>.
- Endler M, Lavelanet A, Cleeve A, Ganatra B, Gomperts R, Gemzell-Danielsson K. Telemedicine for medical abortion: a systematic review. *BJOG An Int J Obstet Gynaecol.* 2019;126(9):1094–102. DOI: <https://doi.org/10.1111/1471-0528.15684>.
- Yang YT, Kozhimannil KB. Medication Abortion Through Telemedicine. *Obstet Gynecol.* 2016;127(2):313–6. DOI: <https://doi.org/10.1097/aog.0000000000001251>.
- Aiken ARA, Lohr PA, Lord J, Ghosh N, Starling J. Effectiveness, safety and acceptability of no-test medical abortion (termination of pregnancy) provided via telemedicine: a national cohort study. *BJOG An Int J Obstet Gynaecol.* 2021;128(9):1464–74. DOI: <https://doi.org/10.1111/1471-0528.16668>.



This work is licensed under a Creative Commons Attribution